

# INJURY OF THE DORSAL SENSORY BRANCH OF THE ULNAR NERVE AS A COMPLICATION OF ARTHROSCOPIC REPAIR OF THE TRIANGULAR FIBROCARILAGE

E. TSU-HSIN CHEN, J. -D. WEI and V. W. S. HUANG

*From the Department of Orthopedic Surgery, Shin Kong Wu Ho-Su Memorial Hospital, Taipei, Taiwan, and Fu Jen Catholic University School of Medicine, Taipei, Taiwan*

**This report presents a case of direct injury to the dorsal sensory branch of the ulnar nerve caused by arthroscopic repair of the triangular fibrocartilage complex. The dorsal sensory branch of the ulnar nerve was strangulated by one of the three pull-out sutures of the joint capsule, just ulnar to the extensor carpi ulnaris tendon. Pain and dysaesthesia of the ulnar side of the wrist was completely relieved after excision of the injured nerve segment. This complication can be avoided by careful exploration of the dorsal sensory branch of the ulnar nerve prior to suturing or passage of instruments during arthroscopy.**

*Journal of Hand Surgery (British and European Volume, 2006) 31B: 5: 530–532*

**Keywords:** wrist arthroscopy, ulnar nerve injury

The rates of neurological complications due to arthroscopy in different series were between 0.1% and 2% (Beredjikian et al., 2004, Rodeo et al., 1993). Although many neural structures are extremely close to the portals used during wrist arthroscopy, the reported rate of neurological complications of wrist arthroscopy is surprisingly low. In 1993, Rodeo argued that the rarity of neurological complications of wrist arthroscopy was probably a result of the infrequency with which this procedure was employed and that it was largely being performed by experienced surgeons who are knowledgeable of hand and wrist anatomy (Rodeo et al., 1993). Following an exponential rise in the use of wrist arthroscopy worldwide over the last 10 years, this is probably no longer the case in 2006, but the incidence of neurological complications remains low. In 2004, Beredjikian and his colleagues reported four cases of neurological complications in 211 (1.9%) wrist arthroscopic procedures (Beredjikian et al., 2004).

This report is a case in which the dorsal sensory branch of the ulnar nerve was injured as a complication of arthroscopic repair of a traumatic triangular fibrocartilage complex (TFCC) tear.

## CASE REPORT

A 21 year-old right-handed man sustained an injury to his left wrist in a traffic accident. No fracture was found after X-ray examination. Arthroscopic surgery was performed for ulnar-sided wrist pain which had persisted for 4 weeks after the accident and identified a Palmer Class 1B TFCC lesion. This lesion was repaired with three percutaneous sutures, using an arthroscope-assisted inside-out technique. However, the patient began experiencing severe pricking pain which radiated to the dorsal aspect of the ring and little fingers soon

after surgery. The patient also experienced pain when rotating his left forearm while performing manual labour and when the operation scar over the TFCC was hit. These pain problems persisted for 4 months and were preventing him carrying out daily activities.

Physical examination identified a 1.5 cm longitudinal scar extending distally from the ulnar styloid of the left wrist (Fig 1). Pronating and supinating the left forearm and light percussion on the operation scar caused severe pain which radiated distally to the dorsum of the ulnar two digits. Exploration by extending the previous wound revealed three stitches of multifilament non-absorbable suture material on the joint capsule, ulnar to the extensor carpi ulnaris tendon. The dorsal sensory branch of the ulnar nerve was caught in the most distal of the three sutures, just proximal to the first bifurcation of this nerve (Fig 2). Segmental excision of the nerve 2 cm proximal and distal to the suture site was performed. The wound was closed with simple sutures, after haemostasis, and covered with a light compressive dressing. The patient experienced immediate pain relief and regained pain-free wrist and forearm movement.

## DISCUSSION

The reported rates of neurological injury resulting from arthroscopic procedures ranged from less than 0.1% to 2% in various series (Beredjikian et al., 2004; Rodeo et al., 1993). Many of these are transient (Beredjikian et al., 2004; Grechenig et al., 1999), but there have been a few reports of neurological injury confirmed by surgical exploration, some of which have been at the wrist. Del Pinal et al. (1999) reported one case of complete avulsion of the distal posterior interosseous nerve at wrist arthroscopy. Lourie reported three cases of transection of the transverse radioulnar branch of the

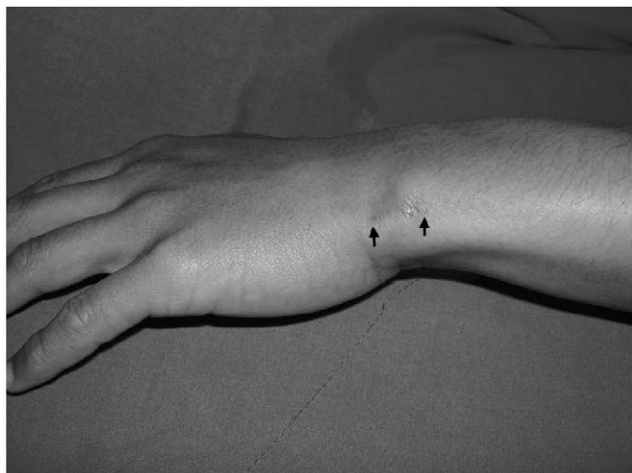

Fig 1 The surgical scar (black arrow) on the ulnar border of the left wrist extending distally from the ulnar styloid at the site of the 6-U portal.

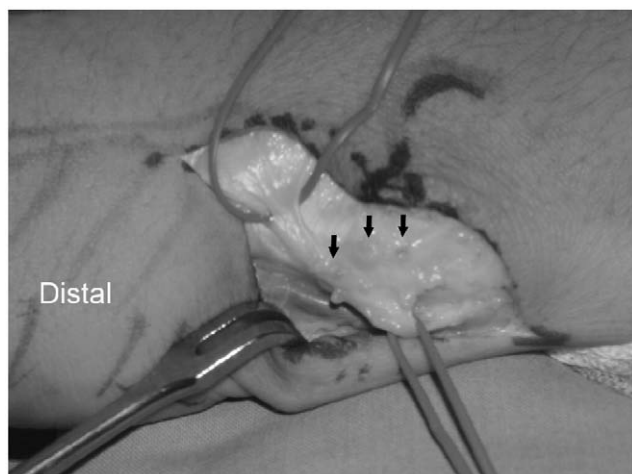


Fig 2 The dorsal sensory branch of the ulnar nerve was identified. Three sutures (black arrow) were identified ulnar to the extensor carpi ulnaris tendon. The most distal suture had strangulated the dorsal sensory branch of the ulnar nerve.

dorsal sensory branch of the ulnar nerve with neuroma formation after surgical procedures such as ganglion excision rather than arthroscopic surgery (Lourie et al., 1994). Lourie's report is of note as the transverse radioulnar branch can be injured during arthroscopy of the distal radioulnar joint.

Triangular fibrocartilage complex injury is a common aetiology of ulnar-sided wrist pain. Arthroscopy is effective in obtaining both correct diagnosis and treatment of these injuries, which cannot always be clearly diagnosed with other imaging techniques, such as arthrography or magnetic resonance imaging. Arthroscopic repair of traumatic triangular fibrocartilage complex tears has been shown to achieve good or

excellent result for more than 85% of patients (Bednar and Osterman, 1994). Nevertheless, nerve injury can occur with this procedure when the sites of portal installation or suture placement are not identified correctly and respected.

Understanding the course and patterns of arborization of the dorsal sensory branch of the ulnar nerve is critical to limiting injury to this nerve by surgeons who operate on the ulnar side of the wrist. According to the study by Botte et al. (1990), the dorsal sensory branch of the ulnar nerve arises from the ulnar nerve deep to the flexor carpi ulnaris tendon and runs subcutaneously across the ulnar border of the forearm approximately 5 cm proximal to the pisiform bone (Botte et al., 1990). The nerve then continues dorsally across the ulnar border of wrist, just distal to the ulnar styloid and directly over the triquetrum and triquetrum-hamate articulation, at an angle of 30° and 45° relative to the long axis of the forearm (Garcia-Elias et al., 2003). With the forearm pronated, the nerve branches may displace slightly palmarly and pass along the palmo-ulnar aspect of the ulnar head (Botte et al., 1990). The nerve has, on average, five branches (range, three to nine branches), with one transverse branch innervating the distal radioulnar joint and the overlying skin in 20 of 24 specimens (Lourie et al., 1994). The course of this branch, when present, is near the 6-R portal for wrist arthroscopy. In a cadaver study, McAdams and Hentz (2002) demonstrated that when performing TFCC repair using the inside-out technique, sutures can be as close as 0.4 mm to the main trunk of the dorsal sensory branch of the ulnar nerve and that, in 50% of the wrists, sutures exited on opposite sides of the nerve. This finding suggested that if the nerve is not located and protected prior to passing sutures through the capsule, there is a 50% chance of strangulating the nerve branch when these sutures are tied.

Technical tips to avoid injury of the dorsal sensory branch of the ulnar nerve had been suggested in various reports. Bednar and Osterman (1994) suggested that pulling out the suture ulnar to the extensor carpi ulnaris tendon or tying the suture on a button over the skin were not safe techniques, whereas making a 1 cm incision just radial to the extensor carpi ulnaris tendon for suture retrieval and tying the suture at the capsule level was safer. McAdams proposed making a longitudinal incision on the ulnar side of wrist to identify the dorsal sensory branch of the ulnar nerve before inserting the needle to avoid cutting the sutures with a scalpel (McAdams and Hentz, 2002). Grechenig suggested inserting instruments through the radial side of the extensor carpi ulnaris tendon (Grechenig et al., 1999). Lourie et al. (1994) emphasized the possibility of injury to the transverse radioulnar branch of the dorsal sensory branch of the ulnar nerve when the 6-R portal is created. Culp (1999) showed that the arborization pattern of the dorsal sensory branch of the ulnar nerve is highly variable, and that nerve injury is possible even when the portals are in the correct locations. This author

suggested that spreading the soft tissues with a fine-point hemostat prior to instrument insertion enables the nerve to slide or move away from blunt instruments. Incising the skin only and identifying the nerve prior to establishing portals or suture passage would seem the most sensible and effective method of avoiding the various branches of the dorsal sensory branch of the ulnar nerve during TFCC arthroscopy.

## References

- Bednar JM, Osterman AL (1994). The role of arthroscopy in the treatment of traumatic triangular fibrocartilage injuries. *Hand Clinics*, 10: 605–614.
- Beredjicklian PK, Bozentka DJ, Leung YL, Monaghan BA (2004). Complications of wrist arthroscopy. *Journal of Hand Surgery*, 29A: 406–411.
- Botte MJ, Cohen MS, Lavernia CJ, von Schroeder HP, Gellman H, Zinberg EM (1990). The dorsal branch of the ulnar nerve: an anatomic study. *Journal of Hand Surgery*, 15A: 603–607.
- Culp RW (1999). Complications of wrist arthroscopy. *Hand Clinics*, 15: 529–535.
- Del Pinal F, Herrero F, Cruz-Camara A, San Jose J (1999). Complete avulsion of the distal posterior interosseous nerve during wrist arthroscopy: a possible cause of persistent pain after arthroscopy. *Journal of Hand Surgery*, 24A: 240–242.

- Garcia-Elias M, Smith DE, Llusá M (2003). Surgical approach to the triangular fibrocartilage complex. *Techniques of Hand and Upper Extremity Surgery*, 7: 134–140.
- Grechenig W, Peicha G, Fellingner M, Seibert FJ, Weiglein AH (1999). Anatomical and safety considerations in establishing portals used for wrist arthroscopy. *Clinical Anatomy*, 12: 179–185.
- Lourie GM, King J, Kleinman WB (1994). The transverse radioulnar branch from the dorsal sensory ulnar nerve: its clinical and anatomical significance further defined. *Journal of Hand Surgery*, 19A: 241–245.
- McAdams T, Hentz V (2002). Injury to the dorsal sensory branch of the ulnar nerve in the arthroscopic repair of the ulnar-sided triangular fibrocartilage tears using an inside-out technique: a cadaver study. *Journal of Hand Surgery*, 27A: 840–844.
- Rodeo SA, Foster RA, Weiland AJ (1993). Current concepts review. Neurological complications due to arthroscopy. *Journal of Bone and Joint Surgery*, 75A: 917–926.

Received: 12 September 2005

Accepted after revision: 27 April 2006

Eric Tsu-Hsin Chen, MD, MS, Department of Orthopedic Surgery, Shin Kong Wu Ho-Su Memorial Hospital, No-95, Wen-Chang Road, Shi-Lin District, Taipei, Taiwan.

Tel.: + 886 227966007; fax: + 886 227922371.

E-mail: tsuhsin@yahoo.com

© 2006 The British Society for Surgery of the Hand. Published by Elsevier Ltd. All rights reserved.

doi:10.1016/j.jhbs.2006.04.026 available online at <http://www.sciencedirect.com>